

Anti-inflammatory effects of montelukast on smoke-induced lung injury in rats

Effetto antinfiammatorio del montelukast sul danno polmonare indotto da fumo nel ratto

Ilknur Basyigit¹, Murat Sahin², Deniz Sahin³, Fusun Yildiz¹, Hasim Boyaci¹, Serap Sirvanci⁴, Feriha Ercan⁴

¹Department of Pulmonary Diseases, School of Medicine, Kocaeli University, Kocaeli, Turkey

²Department of Pulmonary Diseases, Kocaeli Government Hospital, Turkey

³Department of Physiology, School of Medicine, Kocaeli University, Kocaeli, Turkey

⁴Department of Histology and Embryology, School of Medicine, Marmara University, Istanbul, Turkey

ABSTRACT

Aim: To evaluate the effects of montelukast in smoke-induced lung injury.

Methods: 28 Wistar-Albino rats were enrolled into 4 groups with 7 rats per group. The healthy control group was exposed to fresh air while all rats in the 3 experimental groups were exposed to cigarette smoke for 20 weeks for 2 hours per day. After histopathological verification of smoke induced lung injury, montelukast (0.1 mg/kg) dissolved in Na₂CO₃ was given in one group (MON), Na₂CO₃ only was given in another group (MON control) and placebo was injected in the third group (COPD control) intraperitoneally for 21 days. At the end of this period blood samples were obtained for serum TNF- α assessment and light and electron microscopy analyses were performed on the lung tissues of sacrificed rats.

Results: Serum TNF- α levels in the MON group were significantly lower than in the MON control and COPD control groups (38.84 \pm 4.9 pg/ml, 77.5 \pm 5.8 pg/ml and 79.2 \pm 6.9 pg/ml respectively, $p < 0.05$). Furthermore there was no statistically significant difference between the MON group and healthy controls with respect to serum TNF- α levels (38.84 \pm 4.9 pg/ml vs. 29.5 \pm 3.6 pg/ml, $p > 0.05$). Light and electron microscopic evaluation of the lungs demonstrated that the total histopathological damage score of the lung samples was significantly lower in the MON group than in MON controls and COPD controls (5.14 \pm 0.5, 8.4 \pm 0.6 and 8.7 \pm 0.4 respectively, $p < 0.05$), while there was no significant difference between the MON group and healthy controls (5.1 \pm 0.6 vs 2.3 \pm 0.2, $p > 0.05$).

Conclusion: These findings suggest that montelukast might have a protective effect on smoke-induced lung injury in rats both from a histopathological and inflammatory point of view.

Keywords: Chronic bronchitis, inflammation, montelukast, smoking.

RIASSUNTO

Scopo: Valutare gli effetti del montelukast sui danni polmonari indotti dal fumo.

Metodi: 28 ratti Wistar-Albino sono stati suddivisi in 4 gruppi di 7 ratti per gruppo. Il gruppo di controlli normali è stato esposto ad aria pura, mentre tutti i ratti dei 3 gruppi sperimentali sono stati esposti a fumo di sigaretta per 20 settimane per 2 ore al giorno. Dopo la verifica istopatologica del danno polmonare indotto da fumo ad un gruppo è stato somministrato montelukast (0,1 mg/kg) disciolto in Na₂CO₃ (MON), ad un altro gruppo è stato somministrato il solo Na₂CO₃ (controlli MON) e nel terzo gruppo è stato iniettato placebo (controlli COPD) per via intraperitoneale per 21 giorni. Al termine di questo periodo sono stati effettuati prelievi di sangue per il dosaggio del TNF- α serico e sul tessuto polmonare dei ratti sacrificati sono state effettuate analisi al microscopio ottico ed elettronico.

Risultati: I livelli serici di TNF- α nel gruppo MON erano significativamente inferiori ai controlli MON e ai controlli COPD (38,84 \pm 4,9 pg/ml, 77,5 \pm 5,8 pg/ml e 79,2 \pm 6,9 pg/ml rispettivamente; $p < 0,05$). non vi erano inoltre differenze statisticamente significative tra il gruppo MON ed i controlli sani nei livelli serici di TNF- α (38,84 \pm 4,9 pg/ml vs. 29,5 \pm 3,6 pg/ml, $p > 0,05$). La valutazione al microscopio ottico ed elettronico dei tessuti polmonari dimostravano che lo score complessivo di danno istopatologico dei campioni di polmone era significativamente minore nel gruppo MON rispetto ai controlli MON e ai controlli COPD (5,14 \pm 0,5, 8,4 \pm 0,6 and 8,7 \pm 0,4 rispettivamente, $p < 0,05$), mentre non vi erano differenze si-

✉ Ilknur Basyigit

Kocaeli University, School of Medicine, Department of Pulmonary Disease
Umuttepe, 41380 Kocaeli, Turkey
email: ilknur.basyigit@gmail.com

Data di arrivo del testo: 07/12/2009 – Accettato dopo revisione: 19/1/2010

Multidisciplinary Respiratory Medicine 2010; 5(2): 92-98

gnificative tra il gruppo MON ed i controlli sani ($5,1 \pm 0,6$ vs $2,3 \pm 0,2$; $p > 0,05$).

Conclusioni: Questi risultati suggeriscono che il montelukast possa avere un effetto protettivo sul danno polmonare indotto da fumo nei ratti sia dal punto di vista istopatologico che da quello infiammatorio.

Parole chiave: Bronchite cronica, fumo, infiammazione, montelukast.

BACKGROUND

Cigarette smoking induces an abnormal inflammatory response in the airways which is now increasingly acknowledged in the pathogenesis of chronic obstructive pulmonary disease (COPD) [1]. Smoking classically causes neutrophil predominant inflammation in the airways with the increase of neutrophil chemotactic cytokines such as tumor necrosis factor (TNF)- α , interleukin (IL)-8, and leukotriene (LT)B₄ [2-4].

Leukotrienes are generated from the metabolism of arachidonic acid and have significant effects on bronchoconstriction, mucus hypersecretion and airway inflammation [4]. Montelukast is a cysteinyl leukotriene receptor antagonist (LTRA) and widely used as an anti-inflammatory agent in the treatment of asthma [5-7]. Recent studies conducted in smoker and non-smoker asthmatics have shown that inhaled beclomethasone increased forced expiratory volume in 1 sec (FEV₁) levels only in non-smoker asthmatics; on the other hand montelukast increased morning peak flow values only in smoker asthmatics [8]. These data suggested that smoke-induced lung injury might be resistant to inhaled steroids and that LTRA may have possible effects in this setting.

The bronchodilator effects of LTRA in patients with COPD has previously been demonstrated [9,10]. In a recent meta-analysis, Nguyen et al. reviewed 4 placebo-controlled trials investigating the effects of LTRA in the treatment of COPD and concluded that LTRA is associated with significant improvements in FEV₁ levels [11]. The anti-inflammatory effect of montelukast has mostly been investigated in animal models of asthma; therefore data is limited about its effects on smoke-induced inflammation [12,13]. However possible protective effects on smoke-induced lung injury have been previously reported [14].

In this study, our aim was to investigate the possible anti-inflammatory effects of montelukast in rats with smoke-induced chronic bronchitis. Serum TNF- α level was used as a marker of inflammation and a histopathological evaluation of the lung was performed with both light and electron microscopy.

METHODS

Animals

Male Wistar-Albino rats, weighing 250-300 g, were used in this study (n = 28). The rats were kept under standard conditions (stainless-steel cages, 18-21°C,

55-60% relative humidity, and 12 hours light/dark cycles). Standard chow in tablet form and water were available ad libitum. All animals were free from infections.

Rats were exposed to passive cigarette smoke for 20 weeks in order to develop COPD [15] and were decapitated 24 hours after the last injection of the agents; 4 ml of blood was taken intra-cordially for the measurement of serum TNF- α levels. Rat lung tissues were dissected after intra cardiac perfusion. The present study was performed in accordance with the Guiding Principles for the Care and Use of Laboratory Animals; all procedures were approved by the ethics committee of Kocaeli University.

Smoke exposure machine

A special smoke exposure machine based on Chen's definition and Walton's modification was prepared in the Experimental Medicine Research Laboratory of Kocaeli University [16]. Briefly, the machine consisted of three separate chambers connected to each other. The first chamber was a generation chamber where smoke was generated, the second was a residence chamber where smoke was diluted and the third was an exposure chamber where rats were exposed to smoke. Fans between the chambers were used to conduct smoke from one chamber to another, operating at a speed of 5.2 L/min. Standardized nicotine and cigarette tar were used for exposure 2 hours per day for 20 weeks.

Study population

The rats were divided into four groups; smoke exposure and injections were performed in three of the groups while the group of rats without smoke exposure constituted the healthy controls. All injections were performed each day at 09:00 am after development of COPD and continued for 21 days. The study groups and doses of injections were as follows:

1. MON group: 7 rats received 0.1 mg/kg montelukast (Sigma-Aldrich, Italy) dissolved in 1 ml Na₂CO₃ (sodium bicarbonate) intraperitoneally.
2. MON control: 7 rats received 1 ml Na₂CO₃ (Sigma-Aldrich, Italy) intraperitoneally (control group for montelukast).
3. COPD control: 7 rats received 1 ml physiological serum intraperitoneally.
4. Healthy control: the 7 rats in this group were not exposed to smoke; however they were kept in the same machine for 2 hours daily with clean air in order to provide exposure to similar stress.

Histopathological evaluation

Light microscopy: After the perfusion of 2.5% glutaraldehyde, lung tissue specimens were dehydrated in a graded series of ethanol (70%, 80%, 90% and 100%), cleared in toluene and embedded in paraffin. Section paraffin blocks at 5 μ m thickness were stained with hematoxylin and eosin (H&E) and evaluated with an Olympus BH2 photomicroscope (Tokyo, Japan).

Light microscopic results were scored for four

histopathological categories; 1) dilatation of respiratory tract, 2) infiltration of inflammatory cells, 3) proliferation of respiratory epithelium, and 4) vascular congestion. The first three categories were scored from 0 to 3, 0 indicating no pathology and 3 the most severe damage, using a semi-quantitative scale; the last category was scored from 0 to 1 with respect to absence or presence of vascular congestion. The total histopathological score of the lung was calculated as the sum of the scores given for each criterion [17].

Electron microscopic evaluation: After the perfusion of 2.5% glutaraldehyde, lung tissue specimens were post-fixed with 1% osmium tetroxide (0.1 M, pH 7.2), dehydrated in a graded series of ethanol (70%, 80%, 90% and 100%), cleared in toluene and embedded in Epon812 for 24h at 60°C. Semi-thin sections of 1 μ m were cut, stained with toluidine blue and viewed with the light microscope for proper orientation. Tissues were then thin sectioned (60 nm), stained with uranyl acetate and lead citrate and evaluated in a JEOL 1200 SX transmission electron microscope [18].

Serum TNF- α measurement

Blood samples were taken intra-cordially in dry tubes. After centrifugation, serum was aspirated and TNF- α was measured with the ELISA method (Biosource Rat TNF- α kit, CA, USA). TNF- α measurement level was 0-1000 pg/ml.

Statistical analysis

All data were analyzed using the SPSS program version 13.0. The results were expressed as mean \pm standard error (SE). Kruskal-Wallis test was used for statistical comparison of the groups and a $p < 0.05$ was considered as statistically significant.

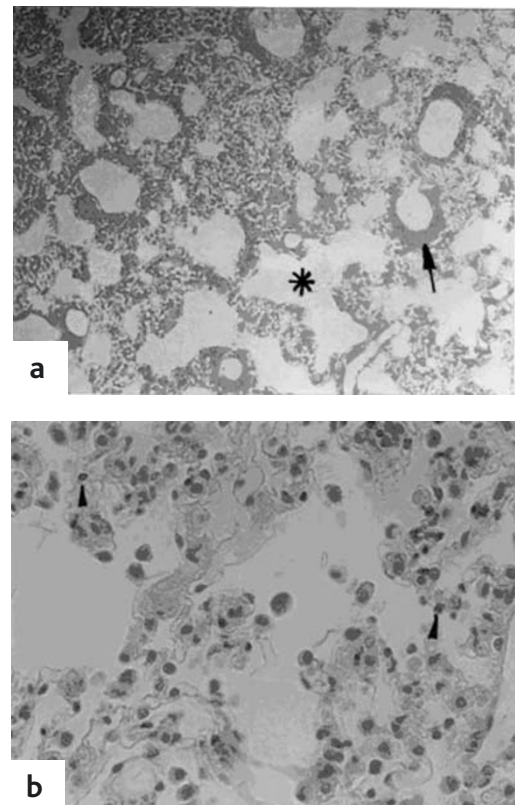
RESULTS

We found dilatation in alveolar duct and respiratory bronchioles, proliferation of alveolar epithelial cells, inflammatory cell infiltration and vascular congestion in the MON control and COPD control groups. The number of type 2 pneumocyte cells and surfactant levels was increased in electron microscope specimens of both groups (Figures 1 and 2). In the MON group, on the other hand, dilatation of alveolar duct was seen less prominently, and there was a decrease in the inflammatory cell infiltration, respiratory epithelial cell proliferation and vascular congestion (Figure 3).

Electron microscopic findings were found to be less improved with montelukast therapy where surfactant deposition and an increase in the number of macrophages were observed (Figure 4).

The total histopathological score was significantly lower in the healthy control group (2.3 ± 0.2) compared to COPD control and MON control groups ($p < 0.001$). However, there was also a significant difference between the montelukast group (MON) and both COPD controls and MON controls (5.1 ± 0.6 in MON vs. 8.4 ± 0.6 in MON controls and 8.7

FIGURE 1: LIGHT MICROSCOPIC FINDINGS OF LUNG TISSUE FROM MONTELUKAST (MON) CONTROL GROUP



Evidence can be seen of (1a) alveolar duct dilatation (*), respiratory epithelial proliferation (→), and (1b) increased inflammatory cell infiltration (▶) (H&E, 1a:X100; 1b:X200).

± 0.4 in COPD controls, $p < 0.05$). There was no significant difference between the healthy control group and the MON group (Figure 5).

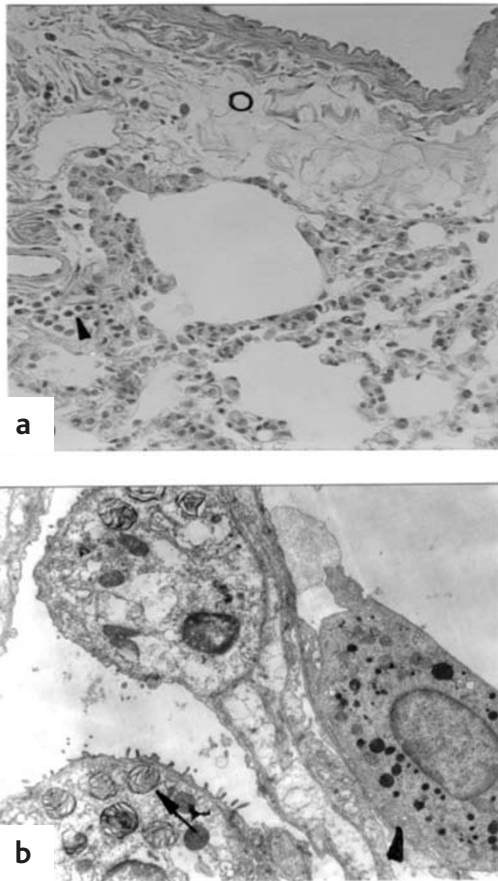
All four categories included in the total histopathological score were also evaluated separately (Table I). We found the inflammatory cell infiltration, respiratory epithelial proliferation and respiratory tract dilatation to be decreased in the smoke-exposed rat lungs of the montelukast group compared to the MON control and COPD control groups. Vascular congestion was found to be less affected by the montelukast treatment.

Smoke exposure caused a significant elevation of serum TNF- α levels in COPD controls and MON controls. However montelukast decreased this elevation to a level comparable with the healthy controls; no significant difference was found between the montelukast group and healthy controls (38.84 ± 4.9 pg/ml vs. 29.5 ± 3.6 pg/ml respectively, $p > 0.05$) (Figure 6).

DISCUSSION

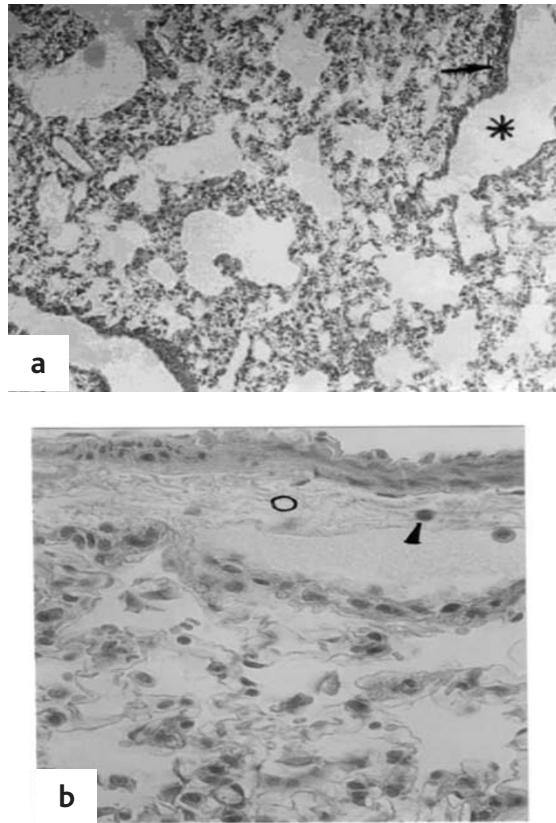
This study demonstrated that montelukast has protective effects on both inflammatory and histopathological aspects of smoke-induced lung

FIGURE 2: LIGHT AND ELECTRON MICROSCOPIC FINDINGS OF COPD CONTROL GROUP



2a: showing inflammatory cell infiltration (▶) and airway wall edema (o) (H&E, X100). **2b:** showing increase in surfactant deposition (→) and increase in the number of macrophages (▶) (X6000).

FIGURE 3: LIGHT MICROSCOPIC EVALUATION OF LUNG TISSUE FROM MONTELUKAST GROUP (MON)



3a: showing alveolar duct dilatation (*) and decrease in respiratory epithelial proliferation (→). **3b:** showing decrease in inflammatory cell infiltration (▶) and arterial wall edema (o) (H&E, 1acX100; 1d:X400).

injury. The effects of smoke exposure in the lung parenchyma was evaluated with light and electron microscopes and montelukast was found to decrease the inflammatory cell infiltration, respiratory cell proliferation, and alveoli-bronchiolar dilatation in smoke-exposed rat lungs. The effects on surfactant deposition and macrophage recruitment in the alveolar space were less prominent; however serum TNF- α levels were shown to be suppressed significantly with montelukast treatment.

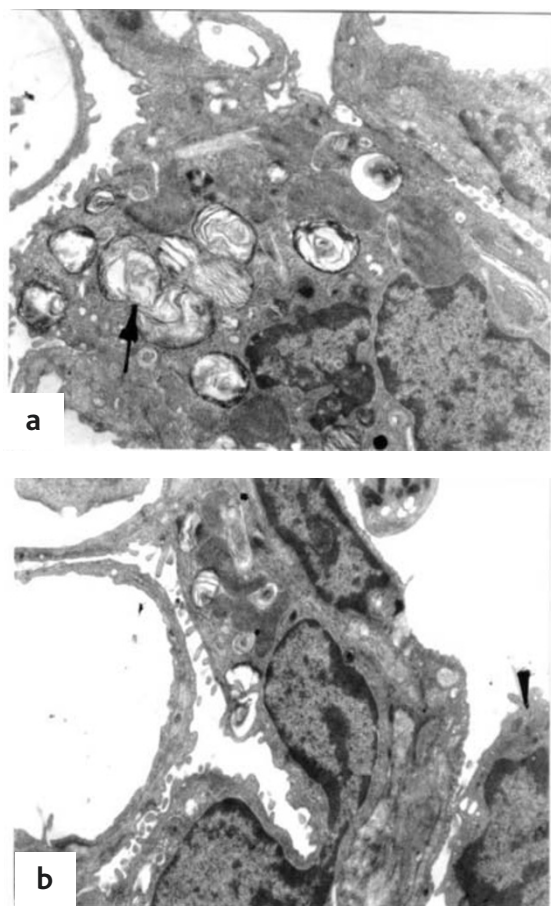
Smoke-induced increase in leukotriene levels and associated changes in the airways such as recruitment of inflammatory cells, vascular congestion, mucus hypersecretion and bronchoconstriction have been shown previously [1,19,20]. In addition, our study displayed significant alveolar dilatation, inflammatory cell infiltration, vascular congestion and surfactant deposition in the smoke exposed rat lung and indicated some beneficial effects of montelukast on such alterations.

Yüksel et al. investigated the effects of montelukast on smoke-induced lung injury in rats [14]. They performed morphometric examinations of lung tissues and counted mast cell numbers in lung parenchyma

besides histopathological evaluation. Using a digital computerized system adapted to a light microscope, they measured linear intercept of alveolar septa as an indicator of airspace dilatation and volume density of alveolar septa and the density of alveolar surface area as indicators of tissue loss. Smoke exposure was found to be associated with alveolar dilatation and tissue loss though significant improvements were noted in the montelukast treated rats. The authors also reported that histopathological alterations such as airspace enlargements, alveolar distortion and visceral pleural thickening were more severe in the smoke-exposed controls than in the montelukast treated group [14]. In our study, a histopathological scoring system was used to evaluate lung parenchyma and, although the methods are not quite the same as those in the study of Yüksel et al., we also demonstrated several protective effects of montelukast on smoke-induced lung injury. In addition, we found a significant decrease in the serum levels of TNF- α in the montelukast treated rats.

TNF- α which is known as a neutrophil chemotactic cytokine has been found to be elevated in human

FIGURE 4: ELECTRON PHOTOMICROGRAPH OF LUNG TISSUE FROM MONTELUKAST GROUP (MON)

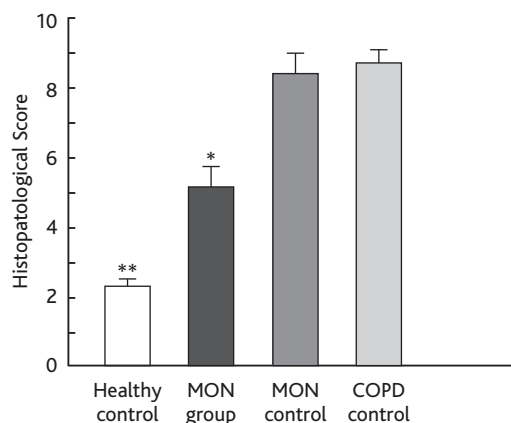


4a showing: increase in surfactant deposition in the type 2 pneumocyte (→). 4b: showing increase in the number of macrophages (▶) (X6000).

smokers and it is thought to have an important role in the pathogenesis of COPD since animal models of smoke exposure showed a strong correlation between serum TNF- α levels and airspace dilatation [21].

Montelukast has been shown to inhibit several pro-inflammatory cytokines in animal models of asthma

FIGURE 5: HISTOPATHOLOGICAL SCORE OF THE LUNG TISSUE SPECIMEN



* p < 0.05; MON group vs. MON control and COPD control groups.

** p < 0.001; healthy controls vs. MON control and COPD control groups.

[12,13]. Maeba et al. reported an inhibitory effect of montelukast on the lipopolysaccharide induced production of IL-1 β , IL-6, TNF- α and MCP-1 from peripheral blood mononuclear cells, while Can et al. showed a decrease in serum TNF- α levels in pediatric asthmatics with montelukast treatment [22,23]. Our study demonstrated the inhibitory effect of montelukast on smoke-induced elevation of serum TNF- α in rats. This finding suggests that, besides its anti-inflammatory effects in asthma, montelukast might also suppress smoke induced inflammation.

Recent studies have reported that smoking may affect the response to anti-inflammatory therapy since smoker asthmatics get less benefit from treatment with inhaled corticosteroid, and have recommended leukotriene antagonists as an alternative anti-inflammatory agent in the treatment of smoker asthmatics [8].

On the other hand, COPD has a distinct association with smoking and is thought to have different inflammatory characteristics from asthmatics. The bronchodilator effects of leukotriene modifiers have been investigated in clinical studies of COPD and

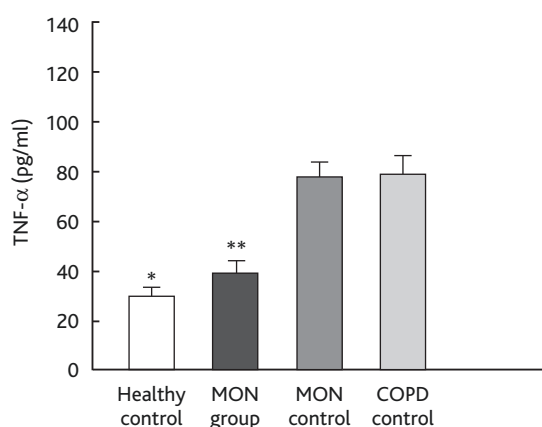
TABLE I: HISTOPATHOLOGICAL SCORE FOR SINGLE PARAMETERS AND TOTAL SCORE

Histopathological categories	Grade range	Groups			
		Healthy control	MON group	MON control	COPD control
Dilatation of respiratory tract	0-3	0.7 ± 0.2	1.7 ± 0.2	2.3 ± 0.3	2.3 ± 0.3
Infiltration of inflammatory cells	0-3	0.6 ± 0.2	1.3 ± 0.2	2.9 ± 0.1	2.9 ± 0.1
Proliferation of respiratory epithelium	0-3	0.9 ± 0.1	1.4 ± 0.2	2.6 ± 0.2	2.7 ± 0.2
Vascular congestion	0-1	0.1 ± 0.1	0.7 ± 0.2	0.7 ± 0.2	0.9 ± 0.1
Total histopathological score	0-10	2.3 ± 0.2**	5.1 ± 0.6*	8.4 ± 0.6	8.7 ± 0.4

* p < 0.05; MON group vs. MON control and COPD control groups.

** p < 0.001; healthy control vs. MON control and COPD control groups.

FIGURE 6: SERUM TNF- α LEVELS OF STUDY GROUPS



* $p < 0.01$; healthy control vs. MON control and COPD control groups.

** $p < 0.05$; MON group vs. MON control and COPD control groups.

improvements in FEV₁ levels were reported [9-11]. Montelukast was also shown to be associated with symptom relief, improvements in the quality of life scores, decrease in the use of inhaled corticosteroids and bronchodilators, and a reduction in exacerbations and hospitalization rates [9,24]. However data are limited about the anti-inflammatory effects of montelukast in smoke-induced inflammation. Celik et al. studied the effects of mon-

telukast on pulmonary function tests and quality of life scores in COPD patients; in this controlled study sputum samples were also obtained for the evaluation of inflammation, which it was possible to examine in 24 patients. Compared to the control group, a significant decrease in neutrophilic inflammation was observed in the montelukast treated group [9]. Although we did not count an exact number of inflammatory cells, our study also demonstrated a significant decrease in inflammatory cell infiltration in the lung parenchyma and a reduction in serum TNF- α , which is thought to be an indicator of neutrophilic inflammation.

There are some limitations of our study as a model of airway inflammation; one may be the lack of inflammatory marker levels in bronchial secretions and the other may be the lack of differential inflammatory cell counts. Nevertheless, we thought that serum levels of TNF- α is an important marker for inflammation in COPD and demonstrating its reduction with montelukast therapy is quite an interesting finding.

In conclusion, treatment with montelukast in smoke-exposed rats is shown to be associated with the suppression of serum TNF- α levels as well as with improvements in histopathological alterations incurred by smoke exposure. Further studies are needed to investigate the use of montelukast as an anti-inflammatory agent in smoke-induced lung diseases.

CONFLICT OF INTEREST STATEMENT: None of the authors has any conflict of interest to declare in relation to the subject matter of this manuscript.

References

1. Carpagnano GE, Kharitonov SA, Foschino-Barbaro MP, Resta O, Gramiccioni E, Barnes PJ. Increased inflammatory markers in the exhaled breath condensate of cigarette smokers. *Eur Respir J* 2003;21:589-593.
2. Tetley TD. Inflammatory cells and chronic obstructive pulmonary disease. *Curr Drug Targets Inflamm Allergy* 2005;4:607-618.
3. Barnes PJ. New molecular targets for the treatment of neutrophilic diseases. *J Allergy Clin Immunol* 2007;119:1055-1062.
4. Riccioni G, Bucciarelli T, Mancini B, Di Ilio C, D'Orazio N. Antileukotriene drugs: clinical application, effectiveness and safety. *Curr Med Chem* 2007;14:1966-1977.
5. Ramsay CF, Sullivan P, Gizycki M, Wang D, Swern AS, Barnes NC, Reiss TF, Jeffery PK. Montelukast and bronchial inflammation in asthma: a randomised, double-blind placebo-controlled trial. *Respir Med* 2009;103:995-1003.
6. Sandrini A, Ferreira IM, Gutierrez C, Jardim JR, Zamel N, Chapman KR. Effect of montelukast on exhaled nitric oxide and nonvolatile markers of inflammation in mild asthma. *Chest* 2003;124:1334-1340.
7. Yildirim Z, Ozlu T, Bulbul Y, Bayram H. Addition of montelukast versus double dose of inhaled budesonide in moderate persistent asthma. *Respirology* 2004;9:243-248.
8. Lazarus SC, Chinchilli VM, Rollings NJ, Boushey HA, Cherniack R, Craig TJ, Deykin A, DiMango E, Fish JE, Ford JG, Israel E, Kiley J, Kraft M, Lemanske RF Jr, Leone FT, Martin RJ, Pesola GR, Peters SP, Sorkness CA, Szeffler SJ, Wechsler ME, Fahy JV; National Heart Lung and Blood Institute's Asthma Clinical Research Network. Smoking affects response to inhaled corticosteroids or leukotriene receptor antagonists in asthma. *Am J Respir Crit Care Med* 2007;175:783-790.
9. Celik P, Sakar A, Havlucu Y, Yuksel H, Turkdogan P, Yorgancioglu A. Short-term effects of montelukast in stable patients with moderate to severe COPD. *Respir Med* 2005;99:444-450.
10. Nannini LJ Jr, Flores DM. Bronchodilator effect of zafirlukast in subjects with chronic obstructive pulmonary disease. *Pulm Pharmacol Ther* 2003;16:307-311.
11. Nguyen M, Woo D. Beyond asthma: a meta-analysis of leukotriene antagonists in the treatment of COPD (abstract). *Chest* 2008;134:p106002.
12. Wu Y, Zhou C, Tao J, Li S. Montelukast prevents the decrease of interleukin-10 and inhibits NF-kappaB activation in inflammatory airway of asthmatic guinea pigs. *Can J Physiol Pharmacol* 2006;84:531-537.
13. Harrison S, Gatti R, Baraldo S, Oliani KL, Andre E, Trevisani M, Gazzieri D, Saetta M, Geppetti P. Montelukast inhibits inflammatory responses in small airways of the Guinea-pig. *Pulm Pharmacol Ther* 2008;21:317-323.
14. Yuksel H, Ozbilgin K, Coskun S, Tuglu I. Protective effects of leukotriene receptor antagonist montelukast on smoking-induced lung injury in Wistar rats. *Acta Med Okayama*

- 2003;57:13-19.
15. Wright JL, Churg A. Animal models of cigarette smoke-induced COPD. *Chest* 2002;122(6 Suppl):S301-S306.
 16. Chen BT, Weber RE, Yeh HC, Lundgren DL, Snipes MB, Mauderly JL. Deposition of cigarette smoke particles in the rat. *Fundam Appl Toxicol* 1989;13:429-438.
 17. Sener G, Topaloğlu N, Sehirli AO, Ercan F, Gedik N. Resveratrol alleviates bleomycin-induced lung injury in rats. *Pulm Pharmacol Ther* 2007;20:642-649.
 18. Akgun S, Tekeli A, Isbir SC, Civelek A, Ak K, Sirvanci S, Arbak S, Yaylim I, Arsan S. FK506 to prevent lung injury after hindlimb ischemia and reperfusion in a rat model: an electron microscopic study. *Surg Today* 2004;34:678-684.
 19. Fauler J, Frölich JC. Cigarette smoking stimulates cysteinyl leukotriene production in man. *Eur J Clin Invest* 1997;27:43-47.
 20. Busse WW, McGill KA, Horwitz RJ. Leukotriene pathway inhibitors in asthma and chronic obstructive pulmonary disease. *Clin Exp Allergy* 1999;29(Suppl 2):110-115.
 21. Churg A, Cosio M, Wright JL. Mechanisms of cigarette smoke-induced COPD: insights from animal models. *Am J Physiol Lung Cell Mol Physiol* 2008;294:L612-L631.
 22. Maeba S, Ichiyama T, Ueno Y, Makata H, Matsubara T, Furukawa S. Effect of montelukast on nuclear factor kappaB activation and proinflammatory molecules. *Ann Allergy Asthma Immunol* 2005;94:670-674.
 23. Can M, Yüksel B, Demirtaş S, Tomaç N. The effect of montelukast on soluble interleukin-2 receptor and tumor necrosis factor alpha in pediatric asthma. *Allergy Asthma Proc* 2006;27:383-386.
 24. Rubinstein I, Kumar B, Schriever C. Long-term montelukast therapy in moderate to severe COPD - a preliminary observation. *Respir Med* 2004;98:134-138.